



## Summary Feedback

### ST1: Two Year Teaching Programme

#### Session 7.4 GIT: Small Intestine

(16<sup>th</sup> June 2022)

Delivered By:

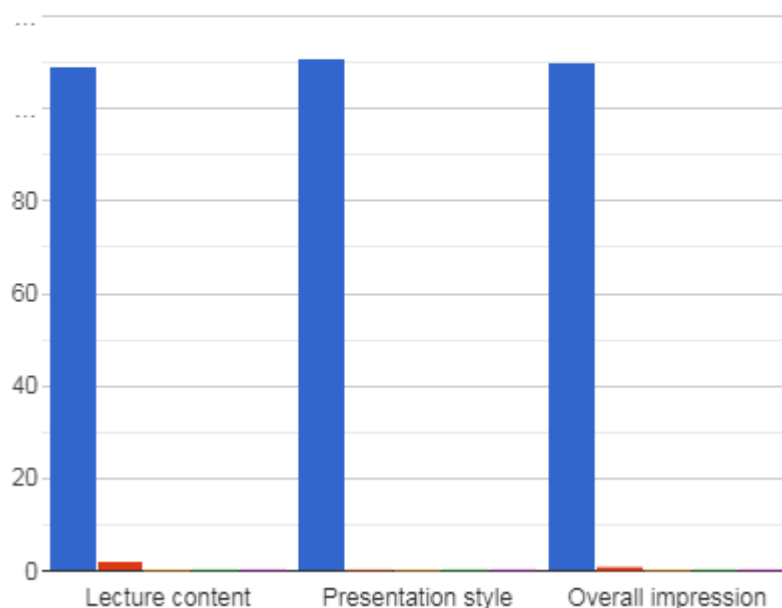
(Sami Khan)

#### Summary Points:

- ST1-ST4 teaching session 7.4: 3 hours teaching time
- Total Attendees: 365 from 30 Countries (Aruba, Bahrain, Bangladesh, Canada, China, Czech Republic, Egypt, Ghana, Hong Kong, India, Indonesia, Iraq, Kenya, Malaysia, Myanmar, Nepal, Nigeria, Oman, Pakistan, Poland, Qatar, Saudi Arabia, South Africa, Sri Lanka, Sudan, UAE, UK, Yemen, Zambia, Zimbabwe).
- Total feedback received from 111 participants

Please rate the following aspects of the session

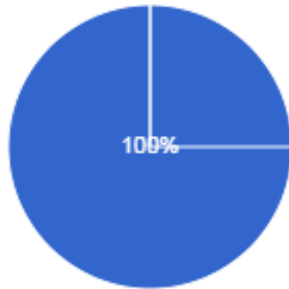
Excellent    Very good    Good    Satisfactory  
Poor



## Session 7.4 GIT - Small Intestine

Did you find it useful  
111 responses

● Yes  
● No



### Testimonials

- Awesome presentations, explanation of cases, clinical and diagnostic points with lateral thinking. Love you sir. God bless you (Pakistan).
- A very brilliant approach in dealing with Mural thickening and enhancement (Egypt).
- Thanks so much to Dr Khan and his Brilliant team for the great work (Pakistan).
- Wonderful session (Kenya).
- Awesome session sir (India).
- Great effort (UK).
- Five stars (Myanmar).
- Flawless (UK).
- Amazing (Pakistan).
- "Thanks a lot Dr. Khan, It was a more than wonderful lecture."
- Marvelous and Superb (Pakistan).
- Excellent session as usual (Sudan).
- Excellent teaching and interesting cases (Algeria).
- Very informative (UAE).
- Very interesting and informative session.
- Great lecture (Kenya).
- Keep it up (Pakistan).
- Brilliant; thanks so much! (UK).
- Thanks for such a wonderful session (Pakistan).
- Very thankful for this platform (Pakistan).
- Excellent teaching session (Egypt).
- Amazing session as always (Pakistan).
- Excellent presentation (Kenya).
- Great presentation (South Africa).
- Great session (Malaysia).
- It's all excellent (Yemen).
- Best way (Pakistan).

## Session 7.4 GIT - Small Intestine

- It is perfect (India).
- All good (Pakistan).
- Brilliant.
- All wonderful (Pakistan).
- I liked a detailed view of anatomy and detailed view of structures on CT and other radiological modalities with clear cut answers (Pakistan).
- Very nice (UK).
- Very informative (UK).
- Great teaching indeed (Pakistan).
- Excellent cases and very informative (Egypt).
- Improved my knowledge (Indonesia).
- Interesting way of approach (Algeria).
- Explained very well.
- Every single case was a learning experience (Pakistan).
- Wonderful cases and clear explanation of the finishing (UK).
- Very detailed explanation (UK).
- Great cases and explanation (UK).
- Excellent session (Pakistan).
- Excellent selection of cases, beautiful explanation, clear discussion of DDs (Pakistan).
- Clear explanation (Kenya).
- Useful and valuable (Yemen).
- Brilliant session (Egypt).
- Very useful and informative (Saudi Arabia).

42 F: Known crohns. Obstructive symptoms. Fibrotic or active stricture?

**Active Disease**

- 1.High intramural T2
- 2.Restricted diffusion

**D/D**

DWI

ADC

Terminal ileum

Participants: 365

Recording to the cloud

American Journal of Roentgenology. 2016;207: 40-48.

Two different patients

Dr Khan's Teaching

Almur Hassan

hamid banday

Sara Yousuf

HUAWEI Y9 Pri...

HUAWEI Y9 Prime 2019

# Small Bowel Studies

1. BMFT  
2. Small Bowel Enteroclysis (Small bowel enema)

1. CT Enterography  
2. CT Enteroclysis

MR Enterography  
MR Enteroclysis

ACR

## MRI Small bowel

1 : 32 : loc

2 : 15 : t2\_hast...

3 : 50 : t2\_trufi...

4 : 50 : t2\_haste...

5 : 30 : t2\_trufi...

6 : 30 : t2\_haste...

7 : 34 : t2\_trufi...

8 : 34 : t2\_hast...

9 : 34 : t2\_hast...

10 : 72 : t1\_vibe...

t1\_vibe...

t1\_vibe...

t1\_vibe...

t1\_vibe...

DWI : b0,b50,b500,b1000

====XX====XX=====